



**AL-NAHRAIN UNIVERSITY
COLLEGE OF MEDICINE**

**((The prevalence of retinopathy in type I
diabetic patients with more than 5 years
of diagnosis))**

**Done by Anas A. Ibraheem
6th grade, AL-Nahrain University College of Medicine
Supervisor: Dr. Jalal A. Ali
M.B.Ch.B. – F.I.C.M.S.
Lecturer at AL-Nahrain University College of Medicine
2018 – 2019**

مَكِّيَّةٌ

سُورَةُ الْعَلَقِ

آيَاتُهَا

بِسْمِ اللَّهِ الرَّحْمَنِ الرَّحِيمِ
اقْرَأْ بِاسْمِ رَبِّكَ الَّذِي خَلَقَ ۝^١ خَلَقَ الْإِنْسَانَ مِنْ
عَلَقٍ ۝^٢ اقْرَأْ وَرَبُّكَ الْأَكْرَمُ ۝^٣ الَّذِي عَلَّمَ بِالْقَلَمِ ۝^٤
عَلَّمَ الْإِنْسَانَ مَا لَمْ يَعْلَمْ ۝^٥ كَلَّا إِنَّ الْإِنْسَانَ لَبَطْغِي ۝^٦

Acknowledgments

I'm very grateful and blessed to have the opportunity to thank my parents, my family and my colleague Namariq Ali for their help during my project and special thank for my best friend Dr. Anas H. Al-Sharqi who always encourages me giving the best and being beside me in the bad days before the good ones.

Dedication

To all people who had been there for me... My family, especially my parents and my best friend Dr. Anas H. Al-Sharqi.

Summery

Background: Diabetic retinopathy is a damage to the retina caused by complications of diabetes, which can eventually lead to blindness. It is an ocular manifestation of diabetes, a systemic disease, which affects up to 80% of all patients who have had diabetes for 10 years, it is a frequent cause of blindness in the United States. DR is the leading cause of blindness in patients aged 20 – 64 years ¹.

Aim: Is to study the prevalence of retinopathy in type I diabetic patients with more than 5 years of diagnosis.

Type of study (design): Cross sectional study.

Patients and method: 30 type I diabetic patients were enrolled in the study who referred to the Ophthalmology clinic from different departments in Al-Imamain Al-Kadhmain Medical City, Baghdad, Iraq.

The patients were examined at our hospital during a period over 2 months, who had previously diagnosed as having type I diabetes mellitus with more than 5 years. (defined as a self-report of a previous diagnosis of the disease by a clinician (excluding gestational diabetes mellitus) or glycated hemoglobin A1c of 6.5% or greater, below age of 30).

The patients completed an interviewer-administered questionnaire then fundus examination was done for those patients by the resident Ophthalmologist for evidence of retinopathy through slit lamp

biomicroscopy with the use of special lenses and mydriatic eye drop for both eyes. At last, completed data was packed into groups to simplify their insertion and calculation then entered in Microsoft Excel program 2016.

Results:

- Total number included in this study was 30 patients. 16 of them are female (53.4%) and 14 are male (46.6%).
- 27 of these define as having diabetic retinopathy (90%).
- Regarding the age, there was no patients younger than 20 years or older than 50 years. In general, 16 (53.4%) of them were between 21-30, 12 (40%) were between 31-40 as both previous age categories carry most DR cases in percentage of (51.8%) and (40.7%) respectively. While 2 (6.6%) were between 41-50 years.
- We found among the cases who have DM for up to 10 years that (77.7%) of them do have DR.
- Most of the patients with more than 10 years of DM were having diabetic retinopathy unfortunately, in a percentage of (95.3%).
- In general, the percentage of diabetic retinopathy is higher in diabetic patients after 10 years as (74.9%) when compared to diabetic patients with 5 up to 10 years as (25.1%).

Conclusion: Diabetic retinopathy is a common health problem between diabetic patients as the prevalence of diabetic retinopathy is increasing with the duration of the disease, diabetes mellitus, the longer a person has diabetes, the higher risk of developing some ocular problem

regardless the stage or the type, the predominate age is more than 10 years of the diagnosis of type I diabetes mellitus.

Recommendations:

- Project to encourage the physicians to send the patients for retinal checkups.
- Education programs to raise awareness about DR screening among the patients. We can reduce the prevalence of diabetic retinopathy by developing an integrated health and social care pathway, further education and better communication between the community and the health care providers through newspapers and television.

Symbols and abbreviations

DM	Diabetes mellitus
DR	Diabetic retinopathy
PDR	Proliferative diabetic retinopathy
PPDR	pre proliferative diabetic retinopathy
IRMA	Intraretinal microvascular abnormality
VEGF	Vascular endothelial growth factor
WHO	World Health Organization
WESDR	Wisconsin Epidemiologic Study of Diabetic Retinopathy
ETDRS	Early Treatment Diabetic Retinopathy Study

Contents of figures

Figure 1: Diabetic retinopathy changes in retina (A) and (B): dots/blots hemorrhages, (C): hard exudate.....	7
Figure 2: PDR, growth of new blood vessels on the retina (A) and (B). showing cotton wool spots (C)	7
Figure 3: Sociodemographic data of the patients regarding the gender.....	11
Figure 4: Sociodemographic data of the patients regarding the age.....	12
Figure 5: The percentage of DR among the patients.....	13
<i>Figure 6: The percentage of DR in patients with more than 5 years up to 10 years from the diagnosis of type I DM.....</i>	<i>14</i>
Figure 7: The percentage of DR in patients with more than 10 years of type I DM.....	14
Figure 8: The percentage of DM duration-related to the presence of retinopathy.....	15

Contents

Summery.....	I
Symbols and abbreviations.....	IV
Contents of figures.....	V

Chapter One: Introduction

Epidemiology.....	1
Pathogenesis.....	1
Risk factors for diabetic retinopathy.....	2
Classification of DR.....	4
Signs and symptoms.....	5
Diagnosis.....	6
Management.....	6

Chapter Two: The Study

Aim.....	8
Patients and methods.....	9
Results.....	11
Discussion.....	16
Conclusion.....	17
Recommendations.....	18
References.....	19

Chapter Three: Appendix

Abstract in Arabic.....	21
Questionnaire form.....	22

Chapter One: Introduction

1-1 Epidemiology:

Diabetes mellitus is a clinical syndrome characterized by hyperglycemia due to absolute or relative deficiency of insulin.² Long-standing metabolic derangement can lead to the development of complications of diabetes, which characteristically affect the eye, kidney and nervous system. ² The prevalence of all types of DR in the diabetic population increases with the duration of diabetes and patient age. DR is rarely found in children younger than 10 years of age, regardless of duration of diabetes. The risk of developing retinopathy increases after puberty ¹. DR is the leading cause of new cases of legal blindness among adults aged 20 to 74 years in the United States³.

1-2 Pathogenesis:

The exact cause of diabetes microvascular disease is unknown. It is believed that exposure to hyperglycemia over an extended period results in several biochemical and physiologic changes that ultimately cause endothelial damage. Specific retinal capillary changes include selective loss of pericytes and basement membrane thickening, which favor capillary occlusion and retinal non-perfusion as well as,

decompensation of the endothelial barrier function, which allow serum leakage and retinal edema to occur. Many hematological and biochemical abnormalities have been correlated with the prevalence and severity of retinopathy ¹:

- 1-Increased platelet adhesiveness.
- 2-Increased erythrocyte aggregation.
- 3-Abnormal serum lipid.
- 4-Defective fibrinolysis.
- 5-Abnormal level of growth hormone. ¹

1-3 Risk factors for DR:

- **Duration of diabetes:** Is the most important risk factor. In patients diagnosed with diabetes before the age of 30 years, the incidence of DR after 10 years is 50%, and after 30 years 90%. DR rarely develops within 5 years of the onset of diabetes or before puberty, but about 5% of type 2 diabetics have DR at presentation. It appears that duration is a stronger predictor for proliferative disease than for maculopathy.⁴

- **Poor control of diabetes:** It has been shown that tight blood glucose control, particularly when instituted early, can prevent or delay the development or progression of DR. However, a sudden improvement in control may be associated with progression of retinopathy in the near term. Type I diabetic patients appear to obtain greater benefit from good control than type II. Raised HbA_{1c} is associated with an increased risk of proliferative disease.⁴

- **Pregnancy:** is sometimes associated with rapid progression of DR, predicating factors include greater pre-pregnancy severity of retinopathy, poor pre-pregnancy control of diabetes, control exerted too rapidly during the early stages of pregnancy, and pre-eclampsia. The risk of progression is related to the severity of DR in the first trimester, if substantial DR is present, frequency of review should reflect individual risk, and can be up to monthly. ⁴

Diabetic macular usually resolves spontaneously after pregnancy and need not be treated if it develops in later pregnancy ⁴

- **Hypertension:** which is very common in patients with type II diabetes, should be rigorously controlled (<140/80 mmHg), Tight control appears to be particularly beneficial in type II diabetics with maculopathy, Cardiovascular disease and previous stroke are also predictive. ⁴

- **Nephropathy:** if severe, is associated with worsening of DR, Conversely, treatment of renal disease (e.g. renal transplantation) may be associated with improvement of retinopathy and a better response to photocoagulation. ⁴

- **Other risk factors:** include hyperlipidemia, smoking, cataract surgery, obesity and anemia. ⁴

1-4 Classification of DR and disease progression:

The classification used in the Early Treatment Diabetic Retinopathy Study (ETDRS– the modified Airlie House classification) is widely used internationally ⁴:

- **Background diabetic retinopathy:** is characterized by micro aneurysms, dot and blot hemorrhages and exudates these are generally the earliest signs of DR and persist as more advanced lesions appear. ⁴

- **Diabetic maculopathy:** strictly refers to the presence of any retinopathy at the macula but is commonly reserved for significant changes, particularly vision-threatening edema and ischemia. ⁴

- **Pre proliferative diabetic retinopathy (PPDR):** manifests with cotton wool spots, venous changes, intra retinal micro vascular anomalies (IRMA) and often deep retinal hemorrhage PPDR indicates progressive retinal ischemia with a heightened risk of progression to retinal neovascularization. ⁴

Cotton wool spots are composed of accumulations of neuronal debris within the nerve fiber layer. They result from ischemic disruption of nerve axons, the swollen ends of which are known as cytooid bodies, seen on light microscopy as globular structures in the nerve fiber layer. As cotton wool spots heal, debris is removed by autolysis and phagocytosis.⁴

- **Proliferative diabetic retinopathy (PDR):** is characterized by neo vascularization on or within the retina itself or new vessels elsewhere in the vitreous body.⁴

- **Advanced diabetic eye disease:** is characterized by tractional retinal detachment significant persistent vitreous hemorrhage. ⁴

1-5 Signs and Symptoms:

Diabetic retinopathy often has no early warning signs. Even macular edema, which may cause vision loss more rapidly, may not have any warning signs for some time and the presence of DR may indicate microcirculatory dysfunction in other organ systems.⁵ In general, however, a person with macular edema is likely to have blurred vision, making it hard to do things like read or drive. In some cases, the vision will get better or worse during the day. In the first stage which is called background diabetic retinopathy there is no symptoms. The only way to detect the disease is by fundus examination, in which microaneurysms (microscopic blood-filled bulges in the artery walls) can be seen, as seen in **figure 1**. If there is reduced vision, fluorescein angiography can be done to see the back of the eye. Narrowing or blocked retinal blood vessels can be seen clearly and this is called retinal ischemia (lack of blood flow). Macular edema may occur in which blood vessels leak contents into the macular region can happen at all stages. The macular oedema symptoms are blurring, darkening or distorted images and it is not the same between two eyes. 10 percent of diabetic patients will get vision loss related to macular oedema. Optical Coherence Tomography can show areas of retinal thickening (fluid accumulation) of macular oedema ⁶. On the second stage, as abnormal new blood vessels (neovascularisation) form at the back of the eye as a part of proliferative diabetic retinopathy (PDR), they can burst and bleed (vitreous hemorrhage) and blur vision, because the new blood vessels are weak, as seen in **figure 2**. The first time this happens, it may not be very severe. In most cases, it will leave just a

few specks of blood, or spots, floating in a person's visual field, though the spots often go away after a few days. patient with DR may complaint from blurred vision in which both eyes are usually affected. Color vision becomes impaired and floaters can be seen. Sometimes they may appear as dark strings or patches which block the person's vision. Poor night vision and sudden total loss of vision could be the presenting symptom. ⁷

1-6 Diagnosis:

Fundoscopy is an examination of the retina in which the eye care professional either looks through a slit lamp biomicroscope with a special magnifying lens that provides a narrow view of the retina or wearing a headset (indirect ophthalmoscope) with a bright light, looks through a special magnifying glass and gains a wide view of the retina. Tonometry and fluorescein angiography are also useful. ¹

1-7 Management:

There are three major treatments for diabetic retinopathy, which are very effective in reducing progressive vision loss from this disease. In fact, even people with advanced retinopathy have a 90 percent chance of keeping their vision when they get treatment before the retina is severely damaged. These three treatments are:

(1) Laser surgery. (2) Injection of corticosteroids or Anti-VEGF into the eye. (3) Vitrectomy. Although these treatments are very successful (in slowing or stopping further vision loss), but they do not cure diabetic retinopathy ¹. Novel agents are emerging, including ranibizumab, a

monoclonal antibody fragment that is anti-angiogenic; it is used for diabetic macular edema. Severe non-proliferative and proliferative retinopathy is treated with retinal photocoagulation, which has been shown to reduce severe visual loss by 85% (50% in maculopathy). Patients must be reviewed regularly to check for recurrence. Vitrectomy may be used in recurrent vitreous hemorrhage that has failed to clear, or tractional retinal detachment threatening the macula. ²

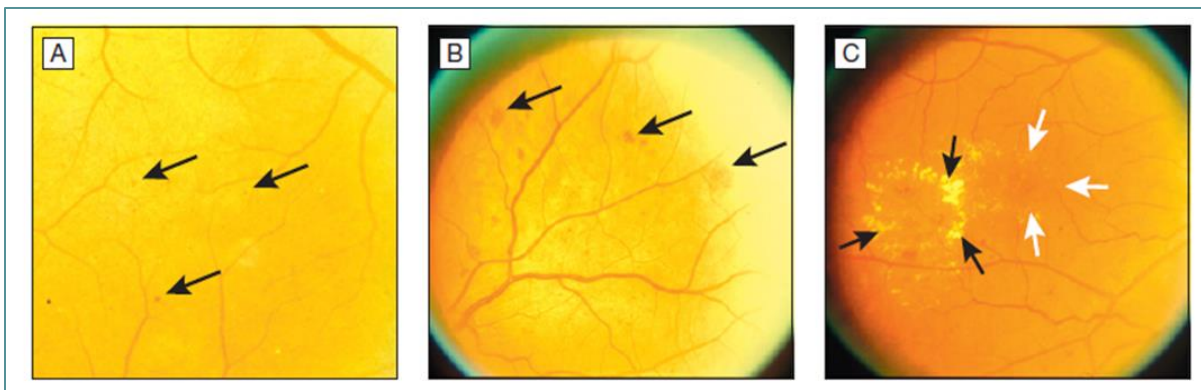


Figure 1: Diabetic retinopathy changes in retina (A) and (B): dots/blots hemorrhages, (C): hard exudate. ²

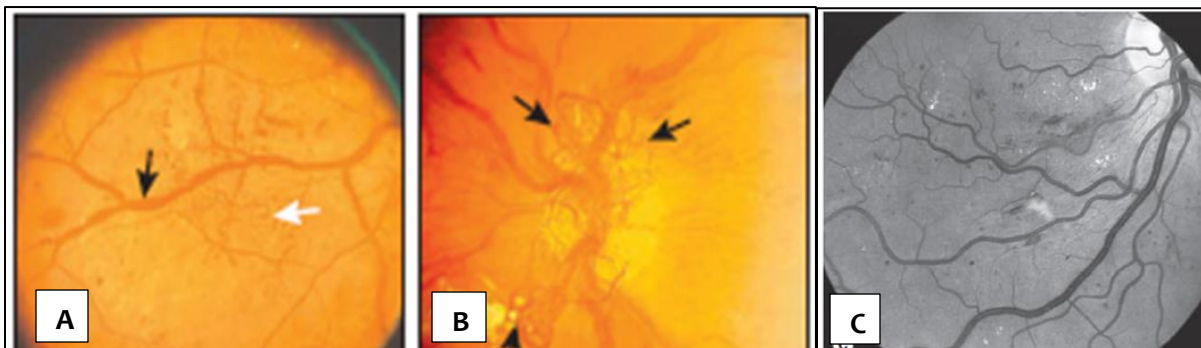


Figure 2: PDR, growth of new blood vessels on the retina (A) and (B). Red-free photography showing differing appearance of cotton wool spots and hemorrhages, the latter appearing black – the smaller well-defined white lesions are exudates (C). ²

Chapter Two: The Study

Aim:

To study the prevalence of diabetic retinopathy in type I diabetic patients with more than 5 years of diagnosis.

Patients and methods:

Overall design: The study was conducted in the out patients Ophthalmology clinic in Al-Imamain Al-Kadhmain Medical City, Baghdad, Iraq.

A hospital based cross sectional study with an attempt to evaluate the prevalence of diabetic retinopathy in sample of patients.

The period of data collection was approximately 2 months which started from 1st of November 2018 to 7th of January 2019.

Selection of the study sample: 30 type I diabetic patients were enrolled in this study as they were referred from different departments in our hospital, including Endocrinology clinic and Medicine ward, to the Ophthalmology clinic for routine eye examination and retinal checkup who had previously diagnosed as having type I diabetes mellitus with more than 5 years.

Diabetes was defined as a self-report of a previous diagnosis of the disease by a clinician (excluding gestational diabetes mellitus) or glycated hemoglobin A1c of 6.5% or greater, below age of 30.⁸

Diabetic retinopathy was defined as the presence of 1 or more retinal microaneurysms or retinal blot hemorrhages with or without more severe lesions (hard exudates, soft exudates, intraretinal microvascular abnormalities, venous beading, retinal new vessels, preretinal and vitreous hemorrhage, and fibroproliferans) using the Early Treatment Diabetic Retinopathy Study (ETDRS) grading standards.⁴

Data collection: The patients completed an interviewer-administered questionnaire carried by the researcher which was including (name, age, sex, duration of diabetes), regarding the questionnaire form, see page 22.

Fundus examination was done for those patients by the resident ophthalmologist in the clinic, after giving them mydriatic eye drops (tropicamide) then their fundi were examined using slit lamp biomicroscopy with 90D lense for both eyes to assess the presence or absence of diabetic retinopathy regardless the type or the severity of the disease.

Statistical analysis: Completed data was packed into groups to simplify their insertion and calculation then entered in Microsoft Excel program 2016.

Results:

From the total 30 patients that have been counsel the Ophthalmology clinic during the mentioned period, 16 of them are female (53.4%) and 14 are male (46.6%), from the total 27 patients who have DR, 13 (48.2%) are female and 14 (51.8%) are male. As seen in **table 1**.

Table 1: Demographical data of the patients regarding the gender and the percentage of DR in relation to it.

The patients' Statistics				
<i>Cases</i>	<i>Number of cases</i>	<i>percentage %</i>	<i>Having DR</i>	<i>percentage %</i>
Female	16	53.4%	13	48.2%
Male	14	46.6%	14	51.8%
Total	30	100%	27	100%

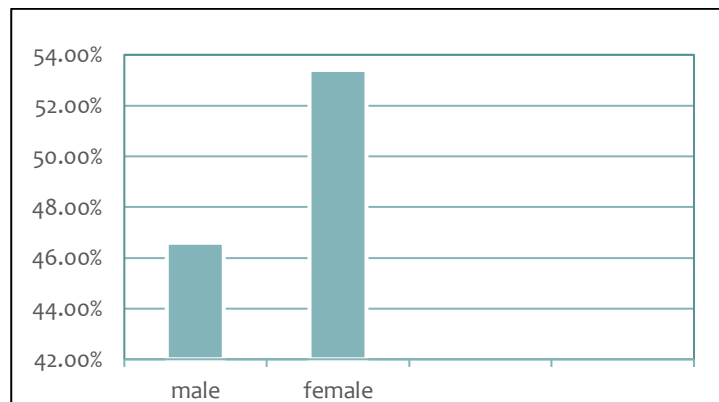


Figure 3: Demographical data of the patients regarding the gender.

Regarding the age, there was no patients younger than 20 years or older than 50 years. In general, 16 (53.4%) of them were between 21-30, 12 (40%)

were between 31-40 as both previous age categories carry most DR cases in percentage of (51.8%) and (40.7%) respectively. While 2 (6.6%) were between 41-50, as seen in **table 2**.

Table 2: Demographical data of the patients regarding the age and the percentage of DR in relation to it.

The patients' Statistics				
<i>Age category (in years)</i>	<i>Number of cases</i>	<i>percentage %</i>	<i>Having DR</i>	<i>Percentage %</i>
10-20	0	0%	0	0%
21-30	16	53.4%	14	51.8%
31-40	12	40%	11	40.7%
41-50	2	6.6%	2	7.5%
>50	0	0%	0	0%
Total	30	100%	27	100%

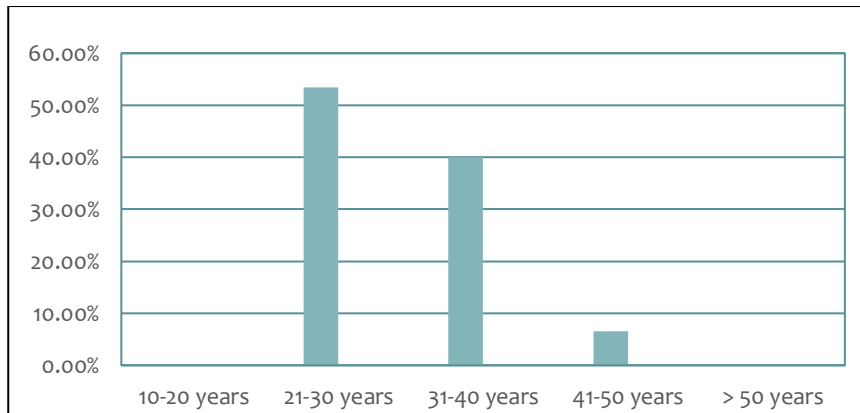


Figure 4: Demographical data of the patients regarding the age.

27 of these patients define as having diabetic retinopathy in a percentage of (90%) who have type I diabetes mellites for more than five years. As seen in **table 3**.

Table 3: The percentage of diabetic retinopathy among the patients.

The patients' Statistics		
<i>Cases</i>	<i>Frequency</i>	<i>percentage %</i>
Having DR	27 /30	90%
Don't have DR	3 /30	10%
Total	30	100%

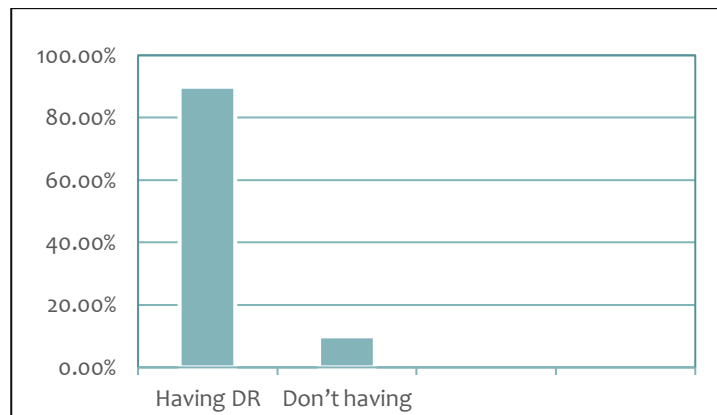


Figure 5: The percentage of diabetic retinopathy among the patients.

Also, we found among the patients who have diabetes mellites for up to 10 years that (77.7%) of them do have diabetic retinopathy, as seen in **table 4**.

Table 4: The percentage of DR in patients with more than 5 years up to 10 years from the diagnosis of type I DM.

The patients' Statistics		
<i>Cases</i>	<i>Frequency</i>	<i>percentage %</i>
Having DR	7 /9	77.7%
Don't have DR	2 /9	22.3%
Total	9	100%

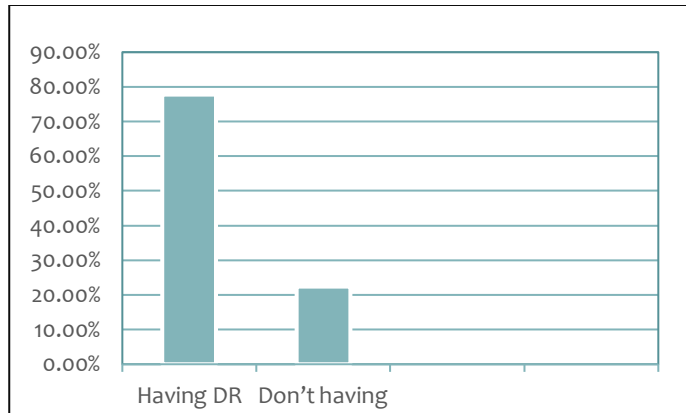


Figure 6: The percentage of DR in patients with more than 5 years up to 10 years from the diagnosis of type I DM.

Most of the patients with more than 10 years of the diagnosis of DM were having diabetic retinopathy, as seen in **table 5**.

Table 5: The percentage of DR in patients with more than 10 years of type I diabetes mellitus.

The patients' Statistics		
<i>Cases</i>	<i>Frequency</i>	<i>Percentage %</i>
Having DR	20 /21	95.3%
Don't have DR	1 /21	4.7%
Total	21	100%

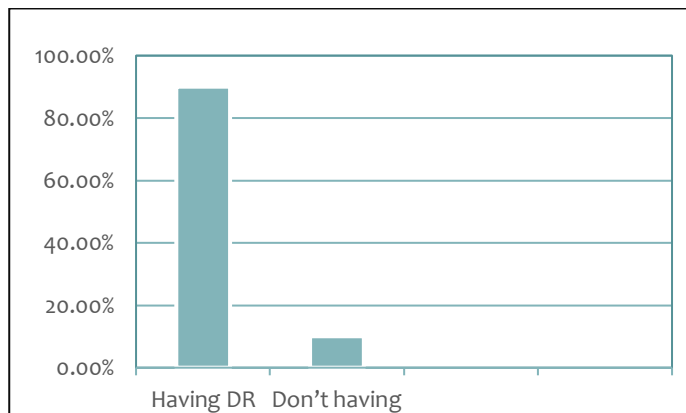


Figure 7: The percentage of DR in patients with more than 10 years of type I DM.

In general, the percentage of DM duration-related to the presence of DR is found to be higher in patients after 10 years of diagnosis as (74.9%) when compared to patients with 5 years up to 10, as in **table 6**.

Table 6: The percentage of DM duration-related to the presence of retinopathy.

The patients' Statistics		
Cases	Frequency	Percentage %
5 years up to 10	7 /27	25.1%
More than 10 years	20 /27	74.9%
Total	27	100%

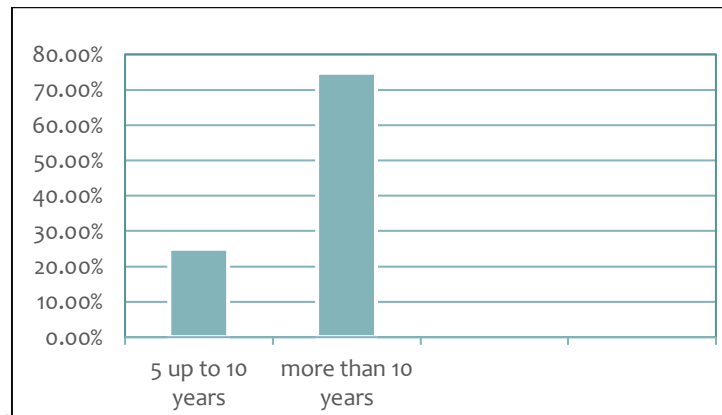


Figure 8: The percentage of DM duration-related to the presence of retinopathy.

Discussion:

Our study is significantly aimed at investigating the prevalence of diabetic retinopathy in type I diabetic patients of more than 5 years of diagnosis, and the prevalence was (90%) overall which is nearly similar to a study made in south of Wisconsin, USA, as the Wisconsin Epidemiologic Study of Diabetic Retinopathy (WESDR) found that among patients with insulin-dependent diabetes with onset before the age of 30, who are presumed to have type I diabetes mellitus, the 4-year cumulative incidence of DR was (59.0%)⁹. At 10, 14 and 25 years, cumulative incidence of DR in the same cohort rose to (89.3%)¹⁰, (95.9%)¹¹ and (97%)¹², beside that earlier population-based studies showed that almost all individuals with type I diabetes and more than 60% of type II diabetes develop diabetic retinopathy during the first 2 decades of the disease³, which can be seen in our results as majority of the patients who have DR are in the second decade of the disease and beyond in a percentage of (95.3%). However, the reported incidence in these studies may not reflect actual DR incidence today, owing to significant advancements in retinopathy diagnosis techniques and risk factor management in the past three decades as we can see in a separate UK study, involving only newly diagnosed cases of type I diabetes recruited between 2000 and 2007, found 9-year cumulative incidence of DR to be only (23.9%)¹³. In Finland, the incidence of VTDR was reported to be decreasing in patients with type I diabetes¹⁴. The variation in rate between our study and the latest studies could be as a result of different methods used in those studies,

the population or the races involved, the sample size and duration of data collection.

From the total 27 patients who have DR, 13 (48.2%) are female and 14 (51.8%) are male which is like a study in Finland ¹⁵ as there is no apparent difference between both genders.

In review of the patients age, there was no patients younger than 20 years or older than 50 years and that could be due to the short duration of data collection despite the limited sample size. DR was between age category (21-50 years) with the majority below the age of 40 which is not much relevant to other studies ^{16 17} as DR increases with age and this variation may be as a result of the same limitations mentioned before regarding the sample size and the duration of data collection.

Conclusion:

Diabetic retinopathy is a common health problem between the patients with DM with more than 5 years of diagnosis as the prevalence of DR increases with the duration of the disease, diabetes mellitus, the longer a person has diabetes, the higher risk of developing some ocular problem regardless the stage or the type. Also, we can rely that the prevalence of DR is higher after 10 years when compared to diabetic patients after 5 up to 10 years from the diagnosis.

Recommendations:

Recommend going further in this study to record many populations and for longer duration and to include other risk factors apart from the duration of the disease to induce DR.

we can reduce the prevalence of diabetic retinopathy by developing an integrated health and social care pathway, further education and better communication between all the relevant parties hence it is extremely crucial to spread knowledge regarding diabetic retinopathy through television, newspaper, posters in all hospitals and other health centers as it will motivate and encourage the diabetic patients to undergo a timely eye examination and thus engage individuals so an initial details and comprehensive eye examination should be performed and project to encourage the physicians to send the patients for retinal checkups to diagnose them earlier and also, educate the patients about the screening schedules of DR, as seen in **table 5**. Subsequent examinations for type I and type II diabetic patients should be repeated annually in the absence of retinal changes, otherwise shorter intervals are recommended ¹⁸.

Table 5: Screening recommendation in patient with diabetes mellitus¹⁸.

Classification	Examination by ophthalmologist or optometrist
Type I diabetes	Within 5 years after onset of diabetes.
Type II diabetes	At time of diabetes diagnosis.

References:

1. T Azar MD, D. (2017). *Basic and clinical science course, 2017-2018*. 3rd ed. [San Francisco]: American Academy of Ophthalmology.
2. Davidson's, Stanley. *Principle and Practice of medicine*, 23rd edition (2018), p.797-836.
3. Fong DS, Aiello L, Gardner TW, et al; American Diabetes Association. Retinopathy in diabetes. *Diabetes Care*. 2004;27:(suppl 1) S84-S87. doi:10.2337/14693935.
4. Kanski, J. and Bowling, B. (2016). *Kanski, Clinical ophthalmology*. 8th ed. Barcelona: Elsevier, pp.520-535.
5. Cheung N, Wong TY. Diabetic retinopathy and systemic vascular complications. *Prog Retin Eye Res*. 2008;27(2):161-176. doi:10.1016/j.preteyeres.2008.02.006.
6. Agardh E, Agardh EC, Torffvit O . A 5-year follow-up study on the incidence of retinopathy in type 1 diabetes mellitus in relation to medical risk indicators. *J Intern Med* 1994; 235:351-358.
7. Schoenfeld ER, Greene JM, Wu SY, Leske MC. Patterns of adherence to diabetes vision care guidelines: baseline findings from the Diabetic Retinopathy Awareness Program in American patients . *Ophthalmology*. 2001;108:563-71.
8. American Diabetes Association. Diagnosis and classification of diabetes mellitus. *Diabetes Care*. 2010;33:(suppl 1) S62-S69. doi:10.2337/10042775.
9. Klein R, Klein BK, Moss SE, Davis MD, DeMets DL. The wisconsin epidemiologic study of diabetic retinopathy: Ix. four-year incidence and progression of diabetic retinopathy when age at diagnosis is less than 30 years. *Arch Ophthalmol*. 1989;107(2):237-43.
10. Klein R, Klein BE, Moss SE, Cruickshanks KJ. The Wisconsin Epidemiologic Study of diabetic retinopathy. XIV. Ten-year incidence and progression of diabetic retinopathy. *Arch Ophthalmol*. 1994;112(9):1217-28.

11. Klein R, Klein BE, Moss SE, Cruickshanks KJ. The Wisconsin Epidemiologic Study of Diabetic Retinopathy: XVII. The 14-year incidence and progression of diabetic retinopathy and associated risk factors in type 1 diabetes. *Ophthalmology*. 1998;105(10):1801–15.
12. Klein R, Knudtson MD, Lee KE, Gangnon R, Klein BE. The Wisconsin Epidemiologic Study of Diabetic Retinopathy: XXII the twenty-five-year progression of retinopathy in persons with type 1 diabetes. *Ophthalmology*. 2008;115(11):1859–68.
13. Martin-Merino E, Fortuny J, Rivero-Ferrer E, Garcia-Rodriguez LA. Incidence of retinal complications in a cohort of newly diagnosed diabetic patients. *PLoS One*. 2014;9(6):e100283.
14. Kyto JP, Harjutsalo V, Forsblom C, Hietala K, Summanen PA, Groop PH. Decline in the cumulative incidence of severe diabetic retinopathy in patients with type 1 diabetes. *Diabetes Care*. 2011;34(9):2005–7.
15. Harjutsalo V, Maric C, Forsblom C, Thorn L, Wadén J, Groop P. Sex-related differences in the long-term risk of microvascular complications by age at onset of type 1 diabetes. *Diabetologia*. 2011;54(8):1992-1999
16. Marshall G, Garg SK, Jackson WE, et al. Factors influencing the onset and progression of diabetic retinopathy in subjects with insulin-dependent diabetes mellitus. *Ophthalmology* 1993;100:1133- 113_9
17. Muh SC, Chie SK, Chin JC, et al. Prevalence and risk factors of diabetic retinopathy among non-insulin dependent diabetic subjects. *Am J Ophthalmology* 1992;114:723-730
18. American Diabetes Association. Standards of medical care in diabetes—2016. *Diabetes Care*. 2016;39(suppl 1):S1-S106.

Chapter Three: Appendix

الخلاصة :

الخلفية : اعتلال الشبكية السكري هو تلف شبكية العين الناتج عن مضاعفات داء السكري والتي قد تؤدي الى فقدان البصر. ونسبة الاعتلال ٨٠٪ من المرضى المصابين بداء السكري لمدة ١٠ سنوات . وانه السبب الرئيسي لفقدان البصر للاعمار التي تتراوح بين ٢٠ - ٦٤ سنة في الولايات المتحدة الامريكية .

هدف البحث : لدراسة نسبة اعتلال الشبكية السكري بين مرضى السكري النوع الاول بعد خمس سنوات من تشخيصهم بالمرض .

المرضى وطرق العمل : تمت الدراسة في استشارية العيون في مدينة الامامين الكاظمين الطبية من تاريخ الاول من تشرين الثاني ٢٠١٨ الى السابع من شباط ٢٠١٩. حيث كان العدد الاجمالي للمرضى المصابون بداء السكري النوع الاول بعد خمس سنوات من التشخيص هو ٤٠ مريضا وتم اخذ المعلومات التالية (الاسم ، العمر ، الجنس ، مدة داء السكري) وبعدها تم فحص شبكية المرضى وتقسيمهم على اساسه الى مجاميع لتسهيل جمع وادخال البيانات.

النتائج : وجدنا أن ٩٠٪ من إجمالي ٣٠ حالة مصابة بداء السكري هم مصابون باعتلال الشبكية السكري بينما ١٠٪ ليس لديهم ، كما وجدنا من بين الحالات التي لديها داء السكري لمدة تصل إلى ١٠ سنوات أن ٧٢,٧٪ منهم لديهم. اعتلال الشبكية السكري. في حين أن ٢٧,٣٪ ليس لديهم . للأسف ، فإن معظم الحالات فوق ١٠ سنوات من التشخيص بداء السكري في الواقع كان لديهم اعتلال الشبكية السكري بنسبة ٩٥٪ بينما ٥٪ فقط لا يملكون . بشكل عام فإن النسبة المئوية لاعتلال الشبكية السكري أعلى في مرضى السكري بعد ١٠ سنوات بنسبة ٧٥٪ بالمقارنة مع مرضى السكري فوق ٥ إلى ١٠ سنوات بنسبة ٢٥٪.

الاستنتاج : نسبة اعتلال الشبكية السكري يزداد مع مدة المرض ، داء السكري ، كلما كان الشخص مصابا بمرض داء السكري لفترة اطول، كلما ازداد خطر حدوث بعض مشاكل العين بغض النظر عن المرحلة أو النوع. وان نسبة اعتلال الشبكية السكري أعلى بعد ١٠ سنوات من التشخيص بداء السكري عند المقارنة مع مرضى السكري بعد ٥ إلى ١٠ سنوات من التشخيص.

التوصيات :

- ١- الشروع لتشجيع الأطباء على إرسال المرضى لفحوصات الشبكية.
- ٢- برامج للتعليم وذلك لزيادة الوعي حول اعتلال الشبكية السكري ولتشجيع الفحص بين المرضى.

Questionnaire form:

NO.....

Name.....

Age.....

Sex.....

When were you diagnosed with type I diabetes mellitus?

After fundal examination, Does the patient have diabetic retinopathy? Yes / No

