



**ALNAHRAIN UNIVERSITY
COLLEGE OF MEDICINE
DEPARTMENT OF MEDICINE**

**FREQUENCY OF DERMATOLOGICA
MANIFESTATIONS IN PATIENTS WITH HYPOTHYROIDISM**

Done by:
Zainab Hazim Abd-Alhussain

Supervised by:
Ass prof. DR.Iqbal Ghalib Al-Tereihi
MBCHB , FICMS(Dermatology and Venereology)

2018-2019

Dedication

“Dedication is not what others expect of you , its is what you can give to others”

This work is dedicated to my family who gave me all love and support , and without whom I wouldn't have accomplished this .

To my fiance who were the light in times of darkness , to you I will always be grateful for making me believe I can reach to where I am now.

**A special dedication to my amazing supervisor , DR.Iqbal Al-Terehi.
,
For her guidance , encouragement and support.**

ACKNOWLEDEMENT

There are number of people without whom this work might not have been possible and to whom I am greatly indebted.

I would like to express my deepest appreciation to my supervisor, DR.Iqbal G. Al-Tereihi , for guiding me with attention and care , and reviewing what I'm doing despite her busy schedule , without her persistent help and support , this work would not have been possible.

My thanks to the department of medicin at Al-Nahrain university , especially endocrinologist at Al-Imamein Al-Kadhemein Medical city for help me to diagnose the cases.

LIST OF CONTENTS

Content	Page no.
Abstract	7
Introduction	9
Aim of the study	17
Patient and method	18
Results	20
Discussion	25
Conclusion	28
Recommendation	28
References	29

LIST OF TABLES

Table	Page no.
Table1	21
Table2	21
Table3	22
Table4	22
Table5	23
Table6	23

LIST OF FIGURES

Figure	Page
Figure1	24
Figure2	24

Abstract

Background: Hypothyroidism is a common endocrine disorder define as the presence of insufficient levels of circulating thyroid hormone (T4), or as target cell resistance to the hormone activity. Thyroxine hormone (T4) regulates essential physiological functions as heart rate, digestion, physical growth, and mental development, an insufficient level of this hormone can cause damage organs and tissues in every part of the body, including the skin .

Aim of study: : To assess the dermatological manifestation on patient with hypothyroidism.

Materials and method: This cross sectional study was conducted in Al-Imamein Al-Kadhemein Medical city from the peroid of October 2018 - March 2019 ,twenty-five patient were enrolled in this study, all of these cases were diagnosed by specialized endocrinologist and investigations was done for diagnosis of hypothyrodism , their age ranged from 26-70 years

The research was done by subjecting the patients to questionnaire form & examination was done for dermatological manifestations.

Results:This prospective clinical study involved 25 diagnosed patients of hypothyroidism, 8 (32%) patients were male and 17 (68%) patients were female. their age range between 26_70 years with average age was 48 years.

Maximum number of patients were in the age group 41-50years was 10(40%) patients, with least number in the age group 61-70 years was 3(12%) patients.

The commonest cutaneous manifestations were hair change 25(100%) patients, nail change 22(88%) patients, Cold intolerance22(88%) patients ,pallor 22(88%) patients, xerosis 17(68%) patients ,pruritis 15(60%) patients , goiter 15(60%) patients , melasma15(60%) patients, hypohydrosis 11(44%) patients,diffuse hyperpigmentation 7(28%) patients, pritibial Myoxedema change 7(28%) patients, periorbital odema 7(28%) patients, malar rash 3(12%) patients, carotenemia 3(12%) patients, Urticria 2(8%) patients, teleangiectasea 2(8%) patients.

all the patients had hair changes the commonest one were diffuse hair loss 17(68%) patients , loss of lateral third of eye brow 17(68%) patients, coarse scalp hair 15(60%) patients , alopecia 12(48%) patients . nail changes were noticed in 22 patients, the commonest one was brittle nail 20(90.9%) patients, loss of cuticle 20(90.9%) patients , Onycholysis 6 (27%) patients, Periungual teleangiectasia 2(9%) patients, Onychomycosis 1(4.5%) patients. Drug history all patient take thyroxine (100%) and there is no side effects.

Conclusion:Hypothyroidism may present as or be associated with many changes in skin, hair and nails. Keeping this in mind, a dermatologist can provide a vital link for early evaluation and detection of hypothyroidism for curative treatment.

Keywords : *Dermatological manifestations, Hypothyroidism*

Introduction:

Hypothyroidism is a common endocrine disorder defined as the presence of insufficient levels of circulating thyroid hormone (T4), or as target cell resistance to the hormone activity [1]. Thyroxine hormone (T4) regulates essential physiological functions as heart rate, digestion, physical growth, and mental development, an insufficient level of this hormone can cause damage organs and tissues in every part of the body, including the skin [2].

Classification: [1]

- a- congenital
- b- primary
- c- secondary
- d- Tertiary

Incidence:

the prevalence of hypothyroidism is between 1 and 2%, and it is more common in older women and 10 times more common in women than in men. The prevalence is higher in surveys of the elderly in the community [3].

Etiopathogenesis [4]:

a. Autoimmune disease.

The most common cause of hypothyroidism known as Hashimoto's thyroiditis. Autoimmune disorders occur when immune system produces antibodies that attack its own thyroid gland.

b. Over-response to ant thyroid drugs.

radioactive iodine or anti-thyroid medications. The goal of these treatments is to get thyroid function back to normal. But sometimes, correcting hyperthyroidism can end up lowering thyroid hormone production too much, resulting in permanent hypothyroidism.

c-Iodine deficiency.

The trace mineral iodine — found primarily in seafood, seaweed, plants grown in iodine-rich soil and iodized salt , It is essential for the production of thyroid hormones. Too little iodine can lead to hypothyroidism, in some parts of the world, iodine deficiency is common,

d-Thyroid surgery.

Removing all or a large portion of thyroid gland can diminish or halt hormone production.

e- Radiation therapy.

Radiation used to treat CA of the head and neck can affect thyroid gland and may lead to hypothyroidism.

f. Others:

1. Pregnancy.

Some women develop hypothyroidism during or after pregnancy (postpartum hypothyroidism), often because they produce antibodies to their own thyroid gland, if Left untreated, hypothyroidism increases the risk of miscarriage, premature delivery and preeclampsia. It can also seriously affect the developing fetus.

2. Medications.

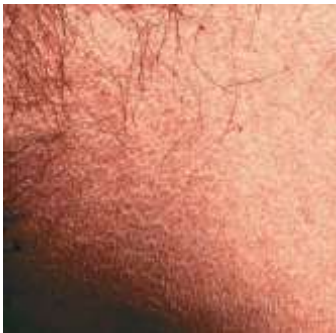Certain drugs that used to treat cardiac problems, psychiatric conditions, and cancer can sometimes affect the production of thyroid hormone. These include: amiodarone, interferon alpha, and interleukin-2[5].

3. Pituitary disorder.

A relatively rare cause of hypothyroidism is the failure of the pituitary gland to produce enough thyroid-stimulating hormone (TSH) usually because of a benign tumor of the pituitary gland.

Dermatological manifestations in hypothyroidism:

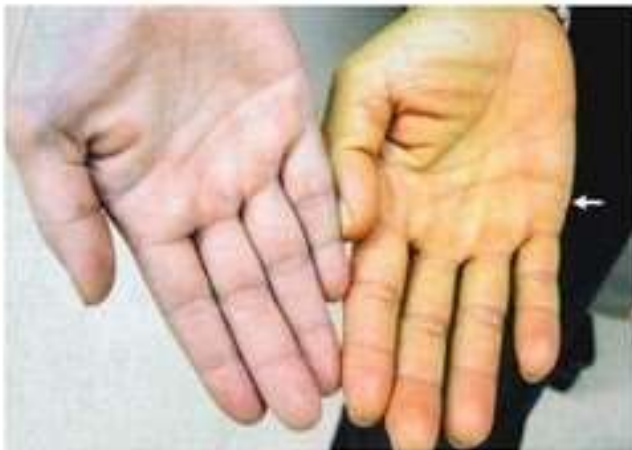1. **Xerosis:** Thyroid hormone is an important regulator of epidermal homeostasis. The skin in hypothyroidism is rough and covered with fine scales . Xerosis may be so severe that it resembles an acquired ichthyosis [6].



[7]

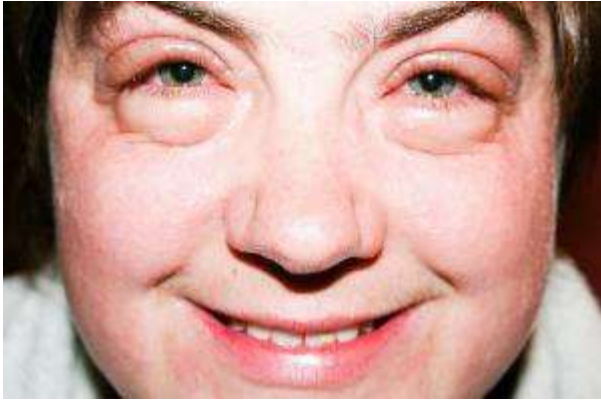2. **pallor** known as pale complexion, because of the dermal mucopolysaccharides and dermal water content [8] .

3. **yellow skin** increased dermal carotene may appear as a prominent yellow hue on the palms, soles and nasolabial folds[8].



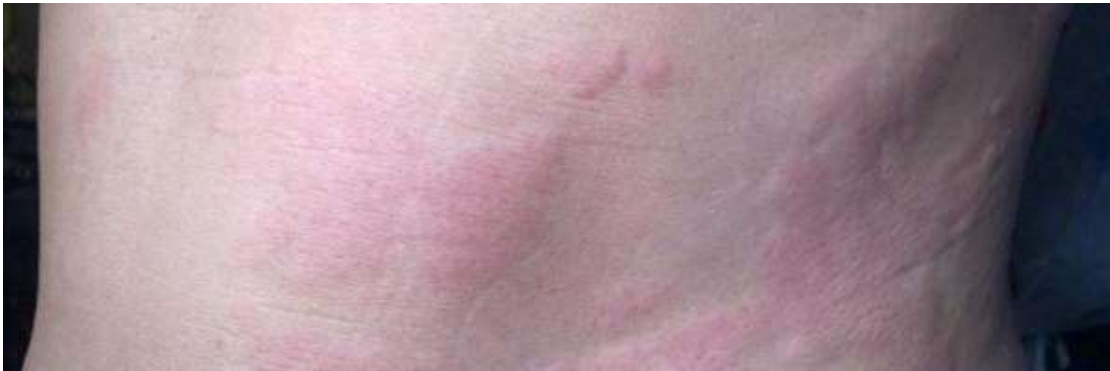[9]

4.**Puffy face** (face. eyelids) Low thyroid function can lead to low temperatures which lead to fluid retention, tight rings, swollen ankles, and puffy face and eyes[10] .



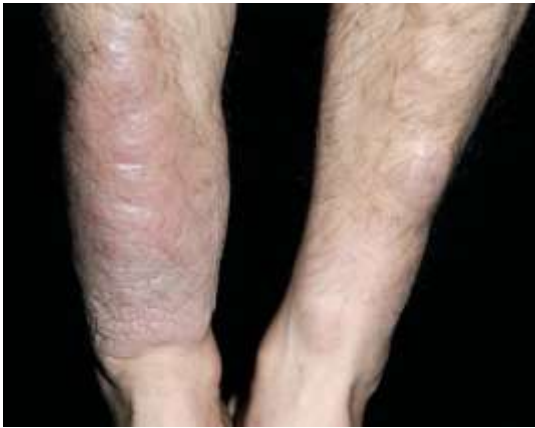[7]

5.**Urticaria** , also known as hives, is an outbreak of swollen, pale red wheals on the skin that appear suddenly -- either as a result of the body's reaction to certain allergens, or for unknown reasons[11] .



[7]

6. **Myxedema** (non pitting edema) results from the accumulation of glycosaminoglycans (GAG) in the dermis, especially hyaluronic acid, secreted by fibroblasts under the stimulation of cytokines due elevation TSH receptor antibodies [12].



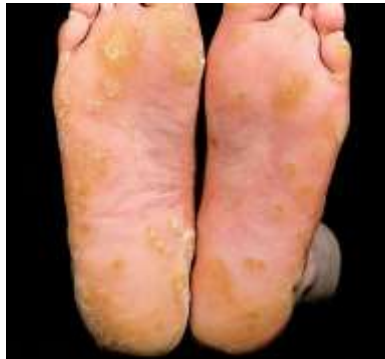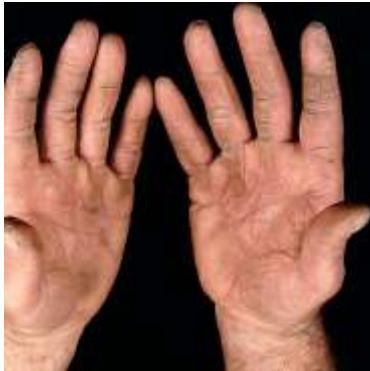[7]

7. **Melasma** is one of the most frequently acquired hyperpigmentation disorders clinically characterized by symmetrical brown patches on sun exposed areas it was found that abnormal levels of TSH are associated with a higher risk of developing melasma. Also, it was found that serum levels of TSH, anti TPO and anti-thyroglobulin are higher in patients with melasma [13].



[7]

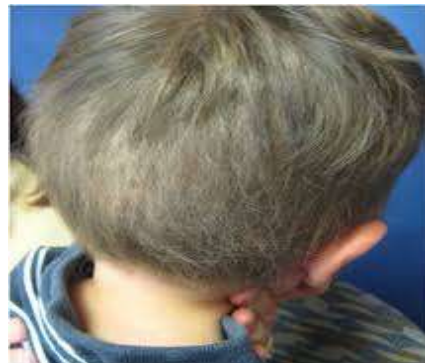8. **Keratoderma** : means marked thickening of the skin. ‘Palmoplantar’ refers to the skin on the soles of the feet and palms of the hands; these are the areas keratoderma affects most often [14].



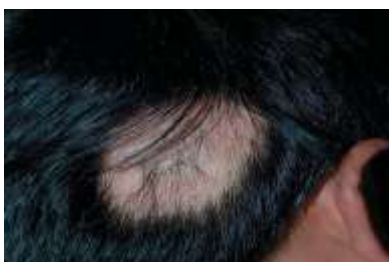[7]

9- Hair change:

I. **dry coarse brittle hair**[15]

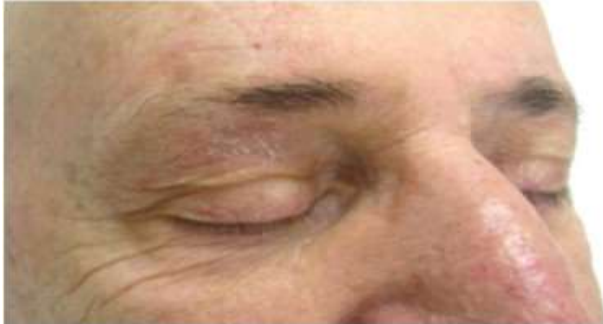

II. **Alopecia areata**, is a condition in which hair is lost from some or all areas of the body.[16].



[7]

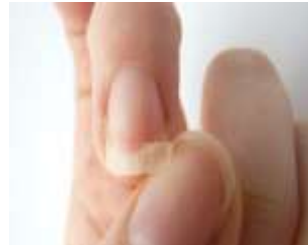III. loss of lateral third of eye brow(madarosis)



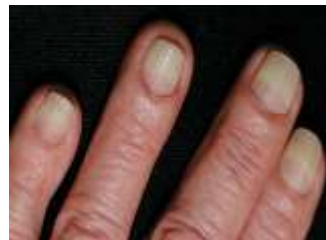[7]

10-Nail change

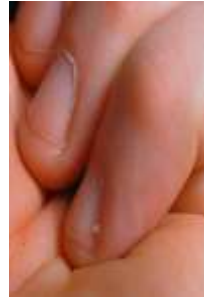brittle nail[17]



, onycholysis [7]



, **cutical loss**[18]



Daignosis of hypothyroidism:

1.clinical Symptom and sign [19]

Appearance • Puffy and pale facies • Dry, brittle hair • Sparse eyebrows
• Dry, cool skin • Thickened and brittle nails • Myxoedema – fluid infiltration of tissues Energy and nutrient metabolism • Cold intolerance
• Weight gain • Fatigue

Nervous system • Headache • Paraesthesias (including carpal tunnel syndrome) • Cerebellar ataxia • Delayed relaxation of deep tendon reflexes Cognitive/ psychiatric • Reduced attention span • Memory deficits • Depression

Cardiovascular • Bradycardia • Diastolic hypertension • Pericardial effusion • Decreased exercise tolerance

Musculoskeletal • Myalgias • Arthralgias

Gastrointestinal • Anorexia • Constipation

Reproductive system • Irregular or heavy menses • Infertility

2- Investigation:[20]

a.thyroid function test(TSH) Normal value 0.5-6 uU/ml [21]if elevated indictate hypothyroidism

b. Free T4 Normal value 0.7-1.9 ng/dl [2] if decreased indicate hypothyroidism.

Aim of this study:

To assess the dermatological manifestation on patient with hypothyroidism.

Patient and Method

This study was conducted in Al-Imamein Al-Kadhemein Medical city from the period of October 2018 - March 2019, twenty-five patients were enrolled in this study, all of these cases were diagnosed by specialized endocrinologist and investigations were done for diagnosis of hypothyroidism, their age ranged from 26-70 years.

The research was done by subjecting the patients to questionnaire form & examination was done for dermatological manifestations.

A questionnaire form was prepared to cover the following points :

NAME :

AGE :

SEX : M F

MARRITAL STATE :

OCCUPATION :

RESIDENCY :

SMOKING & ALCOHOL :

MEDICAL DISEASE

Hyper tension ,DM ,Heart disease

Psychological disease , Other

Drug history

Thyroid function test (TSH ,free T4)

Cutaneous manifestation

1-xerosis 2-pruritis 3-cold on touch
4-thyroid enlargement 5-urticria 6-pale skin
7-hyperpigmentation a-diffuse b-melasma
c-periorbital
8-vitiligo 9-psoriasis 10- acne vulgaris
11-myxedema change 12-lichen planus
13-candidiasis 14-folliculitis 15-dermatophytes
16-polymorphic light eruption 17-SLE
18-pemphigous vulgaris 19-carotenemia
20-kertoderma 21-teleangiectasea
22-periorbital edema 23-eyelid edema 24-pallor

25-ptosis

26-maderosis

27-less sweet

Hair change

1-coarse scalp hair

2-diffuse hair loss

3-alopecia

4-loss of lateral third of eye brow

Nail change

1-brittle nail

2- onycholysis

3-cuticle lost

4-periungual teleangiectasia

5-onychomycosis

Results:

This cross sectional clinical study involved 25 diagnosed patients of hypothyroidism, 8 (32%) patients were male and 17 (68%) patients were female. their age range between 26_70 years with average age was 48 years.

Maximum number of patients were in the age group 41-50years 10 (40%) patients, with least number in the age group 61-70 years 3(12%) patients as shown in table (1)

The commonest cutaneous manifestations were hair change 25(100%) patients , nail change 22(88%) patients, Cold intolerance 22(88%) patients, pallor 22(88%) patients, xerosis 17(68%) patients, pruritis 15(60%) patients , goiter 15(60%) patients, melasma 15(60%) patients, hypohydrosis 11(44%) patients, diffuse hyperpigmentation 7(28%) patients, pretibial Myxedema change 7(28%) patients, periorbital odema 7(28%) patients , malar rash 3(12%) patients , carotenemia 3(12%) patients, Urticria 2(8%) patients , teleangiectasea 2(8%) patients. as described in table (2).

All the patient had hair changes; the commonest one was diffuse hair loss 17(68%) patients, loss of lateral third of eye brow 17(68%) patients, coarse scalp hair 15(60%) patients, alopecia 12(48%) patients, as described in table(3) .

Nail changes were noticed in 22 patients, the commonest one was brittle nail 20(90.9%) patients, loss of cuticle ,20(90.9%) patients, Onycholysis 6 (27%) patients, Periungual teleangiectasia 2(9%) patients, Onychomycosis 1(4.5%) patients; as described in table (4) .

Regarding drug history; all patient take thyroxine 25(100%) patients and there are no side effects.

Medical diseases were noticed in 9(36%) patients of had hypertension, 8 (32%) patients had diabetes mellitus, 6(24%) patients had heart disease; as described in table (5).

Regarding social history; 8(32%) patients were smokers.

Thyroid function test was done to all patients & the results confirm the hypothyroid state as in (table 6).

Table (1): Age distribution among patients with hypothyroidism

Age groups(years)	No.(%)
<30	2(8%)
30-40	6(24%)
41-50	10(40%)
51-60	4(16%)
61-70	3(12%)

Table (2): Cutaneous manifestation distribution among patient with hypothyroidism

Cutaneous manifestation	No.(%) Female	No.(%) Male	Total(%)
Hair change	17(68%)	8(32%)	25(100%)
Nail change	14(63.6%)	8(36.3%)	22(88%)
Cold intolerance	14(63.6%)	8(36.3%)	22(88%)
Pallor	14(63.6%)	8(36.3%)	22(88%)
Xerosis	9(52.9%)	8(47%)	17(68%)
Pruritis	7(46.6%)	8(53.3%)	15(60%)
Goiter	8(53.3%)	7(46.6%)	15(60%)
Melasma	11(73.3%)	4(26.6%)	15(60%)
Hypohydrosis	5(45.4%)	6(54.5%)	11(44%)
Diffuse hyperpigmentation	4(57.1%)	3(42.8%)	7(28%)
Pritibial myxedema	1(14.2%)	6(85.7%)	7(28%)
Periorbital odema	4(57.1%)	3(42.8%)	7(28%)
Malar rash	3(100%)	Zero	3(12%)
Carotenemia	1(33.3%)	2(66.6%)	3(12%)
Urticria	Zero	2(100%)	2(8%)
Teleangiectasea	2(100%)	Zero	2(8%)

Table(3):Hair change distribution among patient with hypothyroidism

Hair change	No.(%) Female	No.(%) Male	Total(%)
Diffuse hair loss	14(82.3%)	3(17.6%)	17(68%)
Loss of lateral third of eye brow	9(52.9%)	8(47%)	17(68%)
Coarse scalp hair	10(66.6%)	5(33.3%)	15(60%)
Alpocia	7(58.3%)	5(41.6%)	12(48%)

Table(4):Nail change distribution among patient with hypothyroidism

Nail change	No.(%) Female	No.(%) Male	No.of patient =22(%)
Brittle nail	13(65%)	7(35%)	20(90.0%)
Loss of cuticle	13(65%)	7(35%)	20(90.9%)
Onycholysis	1(16.6%)	5(83.3%)	6(27%)
Periungual telangiectasia	Zero	2(100%)	2(9%)
Onychomycosis	1(100%)	Zero	1(4.5%)

Table(5):Medical diseases distribution among patient with hypothyroidism

Medical diseases	No.(%) Female	No.(%) Male	No.of patient =25(%)
Hypertension	6(66%)	3(33%)	9(36%)
Diabetes mellitus	4(50%)	4(50%)	8(32%)
Heart disease	2(33%)	4(66%)	6(24%)

Table(6):thyroid function test in patients with hypothyroidism

Thyroid function status	Mean(male)	Median(male)	Mean(female)	Median(female)
TSH(mU/l)	19-8	13.5	19-9	12.5
FT4(pmol/l)	6-2	4	9.2-2	5.6

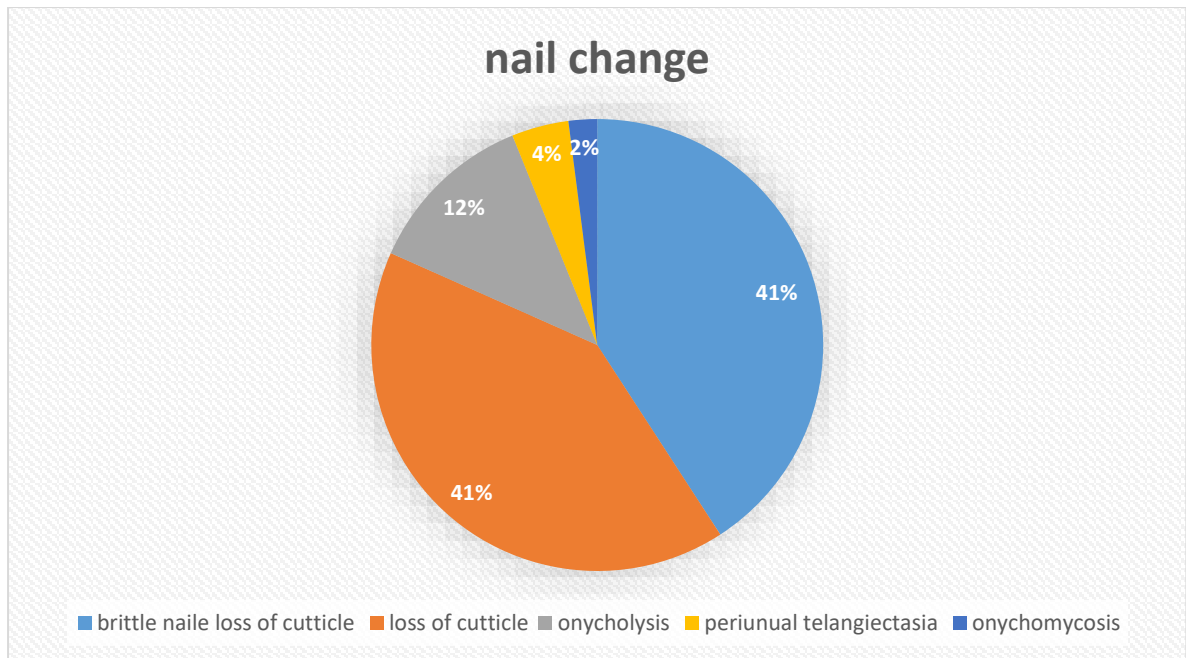


Figure (1) Show nail changes in patients with hypothyrodism

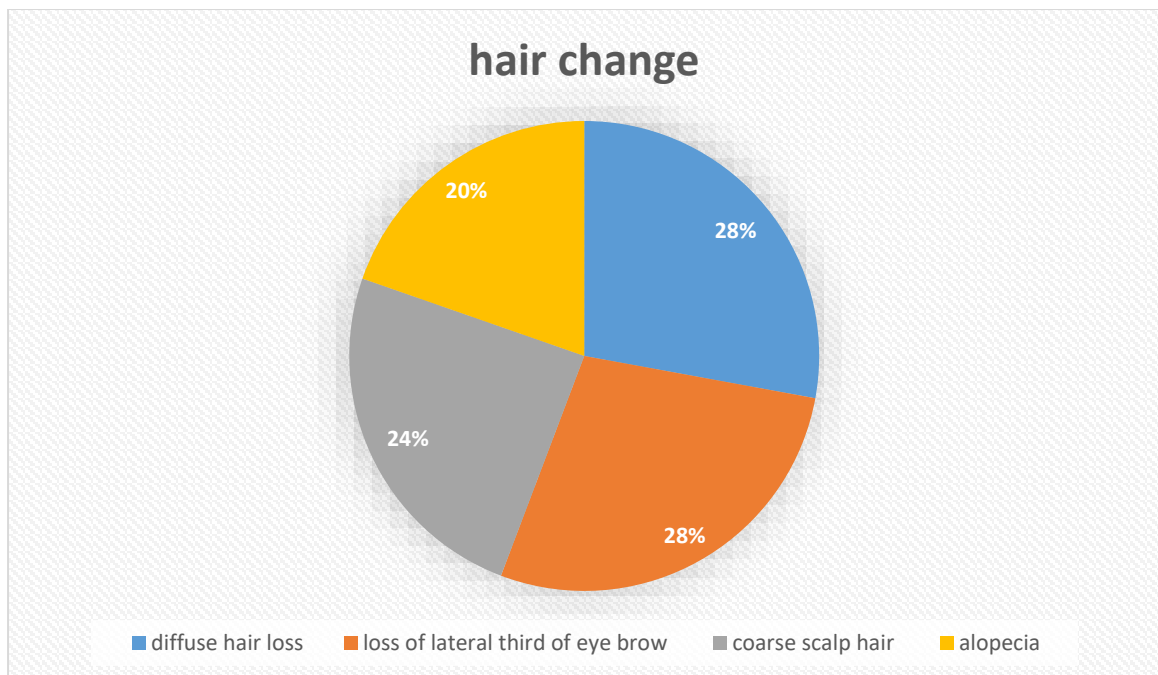


Figure (2) show hair change in patients with hypothyrodism

Discussion

Hypothyroidism is a common endocrine disorder [1], in our study; 25 patients were encountered in this study.

The mean age of patient was 48 years which is higher than other study 37.8 years [Jamwal et al..2013] [22] and 39.15 years [Dogra et al. 2006] [23]. The maximum number of patients were in the age group of 41-50 years 10 (40%) patients similar to study done by [Jamwal et al..2013] [22] and [Indra et al..2004] [24].

Female predominate in our study 17(68%) and 8(32%) male which is the same in study [AJAY PAL SINGH et al..2009] [25] and lower than [Jamwal et al..2013] [22], the female predominate may be due to increased association of autoimmune disorder in female.

The commonest cutaneous manifestations were hair change 25(100%) which higher than study done by [Jamwal et al..2013] [22] Hair loss can be attributed to inhibition of initiation and duration of the actively growing phase of hair cycle. Hence the percentage of hair in telogen increases leading to telogen effluvium. Since the duration of anagen is also affected, the hair growth is slowed with decreased length.

The second most common manifestation were nail change 22(88%), which is higher than study done by [Jamwal et al..2013] [22].

Cold intolerance 22(88%) which is higher than study done by [Frederick Paswett et al..2016] [26] Hypothermia is a result of hypo metabolic state which causes reduced core temperature and reflex cutaneous vasoconstriction as reported by Mullin GE.[27]

Pallor was found in 22(88%) patients which is higher than study done by [Jamwal et al..2013] [22] It develops as a normal response to decreased oxygen requirement and results in decrease in erythropoietin and erythropoiesis with a slight bone marrow hypoplasia [28] and also due cutaneous vasoconstriction [29].

Xerosis was found in 17(68%) patients which was similar to the study done by [Jamwal et al..2013] [22]. Dryness of skin is due to diminished eccrine and sebaceous gland activity and also because of decreased sweating due to cytological changes in the sweat glands in hypothyroidism [30]

Pruritus was found in 15(60%) patients which is higher than study done by [Jamwal et al..2013] [22]. Pruritus can be explained by decreased activity of sweat glands, sebaceous glands and low epidermal sterol synthesis [31]

goiter was found in 15(60%) patients which is higher than study done by [Frederick Paswett et al..2016] [26]

melisma was found in 15(60%)patients which is similar to study done by [Jamwal et al..2013] [22]. The hyperpigmentation may be due to increased release of pituitary adrenocorticotrophic hormone, compensating for the cortical insufficiency, secondary to severe long standing hypothyroidism [32] [33].

hypohydrosis was found in 11(44%) patients which is higher than study done by [Jamwal et al..2013] [22]

Diffuse hyperpigmentation was found in 7(28%) patients which is higher than study done by [Frederic Paswett et al..2016] [26]

Pretibial Myxedema change was found in 7(28%) patients which is higher than study done by [Frederick Paswett et al..2016] [26]

Periorbital odema was found in 7(28%) patients which is lower than study done by [Jamwal et al..2013] [22]. Facial puffiness is related to tissue infiltration with muco-polysaccharides predominantly in the papillary dermis around the vessels and appendages, and also increase in tissue sodium concentration with associated water retention[34]

Malar rash was found in 3(12%) patient which is higher than study done by [Frederick Paswett et al..2016] [26]

Carotenemia was found in 3(12%) patients which is higher than study done by [Jamwal et al..2013] [22] , this is due to reduced conversion of β -carotene to vitamin A in liver and increased blood levels of carotene lead to accumulation of carotene in stratum corneum[35].

Urticria was found in 2(8%) patients which is lower than study done by [Jamwal et al..2013] [22] because of autoimmunity[36].

The most common hair finding was diffuse hair loss 17(68%) patients similar to study done by [Jamwal et al..2013] [22], , loss of lateral third of eye brow 17(68%) patients not found in other study , coarse scalp hair 15(60%) patients which is higher than study done by [Jamwal et al..2013] [22] The reason for coarse, dry and brittle hair in our patients is due to diminished sebum secretion[37] ,alopecia 12(48%) patients which is higher than study done by [Jamwal et al..2013] [22] This been due to autoimmunity associated with thyroid disorders, is especially Hashimoto's thyroiditis

The most common nail finding was brittle nail 20(90.9%) patients which is higher than study done by [Jamwal et al..2013] [22], loss of cuticle ,20(90.9%) patients, Onycholysis 6 (27%)patients , periungual teleangiectasia 2(9%) patients were higher than the study done by [Jamwal et al..2013] [22].

Conclusion

Hypothyroidism may present as or be associated with many changes in skin, hair and nails. Keeping this in mind, a dermatologist can provide a vital link for early evaluation and detection of hypothyroidism for curative treatment.

Recommendations:

A multicentric study with larger sample size would reduce the bias of the study.

Referances

1. Zanni MSG, Campana R, Papa M, Ragazzini L, Monetti E, Trakal JJ. Cutaneous manifestations in hypothyroid patients. *Dermatologia Argentina* 2008;14 3 :196-9.
2. American Thyroid Association. Montefiore Medical Center, 111 E. 210th St., Bronx, NY 10467.
3. Vanderpump MPJ. Braverman LE, Utiger RD. The epidemiology of thyroid diseases, Werner and Ingbar's *The Thyroid: A Fundamental and Clinical Text*, 2005 9th edn Philadelphia JB Lippincott-Raven (pg. 398-496)/ Parle JV, Franklyn JA, Cross KW, et al. Prevalence and follow-up of abnormal thyrotrophin (TSH) concentrations in the elderly in the United Kingdom, *Clin Endocrinol (Oxf)*, 1991, vol. 34 (pg. 77-83)
4. AskMayoExpert. Hypothyroidism. Rochester, Minn.: Mayo Foundation for Medical Education and Research; 2018.
5. Reviewed by Laura J. Martin, MD on August 13, 2017
6. Heymann WR. Cutaneous manifestations of thyroid disease. *J Am Acad Dermatol.* 1992;26:885. [PubMed]
7. <https://www.dropbox.com/s/jcbnc54pvq9hyhh/Fitzpatrick%20Color%20Atlas%20and%20Synopsis%20of%20Clinical%20Dermatology.pdf?dl=0>
8. Reuter MJ. Histopathology of the skin in myxedema. *Archives of Dermatology and Syphilology.* 1931;24:55–71.
9. <https://goo.gl/images/ijNSTL>
10. <https://www.wilsonssyndrome.com/thyroid-and-fluid-retention/>
11. Reviewed by Stephanie S. Gardner, MD on October 12, 2017
12. <https://www.uptodate.com/contents/pretibial-myxedema-thyroid-dermopathy-in-autoimmune-thyroid-disease/abstract/4>
<https://www.uptodate.com/contents/pretibial-myxedema-thyroid-dermopathy-in-autoimmune-thyroid-disease/abstract/>
13. Mogaddam, M.R., Alamdari, M.I., Maleki, N. Ardabili, N. Abedkouhi, S. Evaluation of auotimmune thyroid disease in melasma. *J Cosmet Dermatol.* 2015 Jun;14(2):167-71.
14. Talae, R., Ghafarpassand, I., Masror, H. The Relationship Between Melasma and Disturbances in the Serum Level of Thyroid Hormones and Indices. *Open Science.* 2015;2(2):19-23.
14. Author: Dr Amy Stanway, Dermatology Registrar, Nottingham, United Kingdom, 2005.
15. <https://goo.gl/images/2naUMe>
16. "Alopecia Areata - NORD (National Organization for Rare Disorders)". NORD (National Organization for Rare Disorders).

2004. Archived from the original on 21 February 2017. Retrieved 10 July 2017.
17. https://www.google.com/imgres?imgurl=https%3A%2F%2Fwww.homeremedyhacks.com%2Fwp-content%2Fuploads%2F2016%2F03%2FHome-Remedies-for-Brittle-Nails-696x451.jpg&imgrefurl=https%3A%2F%2Fwww.homeremedyhacks.com%2F20-simple-home-remedies-strengthening-weak-nails%2F&tbid=DRcTP_PuLXF_sM&vet=1&docid=jzDAswUPpsntRM&w=696&h=451&hl=ar-iq
 18. <https://goo.gl/images/3Yt4px>
 19. American Association of Clinical Endocrinologists. Thyroid Guidelines Committee. AACE medical guidelines for clinical practice for the evaluation and treatment of hyperthyroidism and hypothyroidism. *Endocr Pract* 2002;8:457–69. Search PubMed
 20. Topliss DJ, Creswell JE. Diagnosis and management of hyperthyroidism and hypothyroidism. *Med J Aust* 2004;180:186–93. Search PubMed
 21. <http://www.btf-thyroid.org/information/leaflets/34-thyroid-function-tests-guide>
 22. Jamwal A, Sharma A, Rather PA. Cutaneous Manifestations of Hypothyroidism: Prospective Hospital Based Clinical Study. *J Adv Med Dent Scie* 2013;1(2):5-12.
 23. Dogra A, Dua A, Singh P. Thyroid and skin. *Indian J Dermatol* 2006; 51: 96-99.
 24. Indra R, Patil SS, Joshi R, Pai M, Kalantri SP. Accuracy of physical examination in the diagnosis of hypothyroidism;a crosssectional; double blind study. *J Postgraduate Med* 2004: 50: 7.
 25. <https://documentcloud.adobe.com/link/track?uri=urn%3Aaaid%3Aascds%3AUS%3A0ebf01ae-c3a0-4b6f-999a-0cb41b6c44b1>
 26. <https://documentcloud.adobe.com/link/track?uri=urn%3Aaaid%3Aascds%3AUS%3Abf99b6af-74f9-4b73-a3b2-946a7fe4b54a>
 27. Mullin GE, Eastern JS. Cutaneous signs of thyroid disease. *Am Fam Physician* 1986;34 4 :93-8.
 28. Wiersinga WM. Hypothyroidism and myxedema coma. *Endocrinology* 5th edition, 1999: 2081-2086.
 29. Tonacchera M, Chiovato L, Pinchera A. Clinical assessment manifestations of and systemic hypothyroidism.
 30. Means MA, Dobson RL. Cytological changes in the sweat gland in hypothyroidism. *J Am Med Assoc* 1963; 186: 113-5.

31. . Khopkar U, Pande S. Etiopathogenesis of pruritus due to systemic causes: Implications for treatment. *Indian J Dermatol Venereol Leprol* 2007; 73: 215-7.
32. Larsen PR, Davies TF. Hypothyroidism and Thyroiditis. *William's Textbook of Endocrinology* 9th edition, 1998: 423-455.
33. Niepomniszcze H, Amad RH. Skin disorders and thyroid diseases. *J Endocrinol Invest* 2001; 24: 628-38.
34. Bernhard JD, Freedberg IM, Vogel LN. The Skin in Hypothyroid. *Werner and Ingbar's The Thyroid* 7th ed 1996; 792-5.
35. Jabbour SA, Miller JL. Endocrinopathies and the skin. *Int J Dermatol* 2000; 39: 88-99.
36. Leznoff A, Sussman GL. Syndrome of idiopathic chronic urticaria and angioedema with thyroid autoimmunity: A study of 90 patients. *J Allergy Clin Immunol* 1989; 84: 66-71.
37. Warin AP. Eczema craquele as the presenting feature of myxoedema. *British J Dermatol* 1973; 89: 289-91.